

## New Technique for Management of Relaxed Vagina – Preliminary Study

Vishwa Prakash<sup>1\*</sup> and Neeta Garg<sup>2</sup>

<sup>1</sup>Department of Plastic Surgery, Safdarjung Hospital, New Delhi, India

<sup>2</sup>Gynaecologist, Centre for Female Genital Reconstruction, Indrapuram, Ghaziabad, India

### Abstract

Sexual health is vital to overall well-being. Orgasm is a normal psycho-physiological function of human beings and every woman has the right to feel sexual pleasure. Vaginal and clitoral orgasms are essential for heightened sexual pleasure for which tight vagina having the capability of exerting sufficient pressure over glans penis is essential. Relaxed vagina cannot apply enough pressure over penis during sex and so both vaginal and clitoral orgasms are diminished in intensity. Gynaecologists world over do not recognize the loose vagina in isolation and therefore no proper procedure had been described for correction of loose vagina. We for the first time described a new technique for management of loose vagina in 21 patients and achieved good results.

**Keywords:** Vagina; Orgasm; Rugae

### Introduction

Sexual health is vital to overall well-being. Orgasm is a normal psycho-physiological function of human beings and every woman has the right to feel sexual pleasure [1]. Vaginal and clitoral orgasms are essential for heightened sexual pleasure for which tight vagina having the capability of exerting sufficient pressure over glans penis is essential. Relaxed vagina cannot apply enough pressure over penis during sex and so both vaginal and clitoral orgasms are diminished in intensity. Data obtained from 78 white females and 64 black females indicate that resting pressure approximates 5 mmHg and pressure with appropriate pelvic musculature contracted reaches an average of 15 mmHg in vagina. In relaxed vagina pressure never reaches 15mmHg and so during sex pressure over penis is nil or negligible [2]. Relaxed vagina impairs urethral stimulation in women so that “urethro-corporocavernosal reflex.” is affected and ‘Sinusoidal and cavernosus muscles’ response during coitus is hampered which effect a degree of tumescence for both male and female partners [3]. Loose vagina also does not increase the clitoral blood flow which due to which good clitoral orgasm cannot be achieved in loose vagina.

Relaxed vagina may be present in isolation or part of pelvic relaxation syndrome. Different varieties of cystoceles and rectoceles are associated with relaxed vagina; their treatment is primarily directed to management of pelvic relaxation. However over the centuries what we have forgot to realize that there is definite set of patients suffering with vaginal relaxation without cystocele rectocele and pelvic relaxation. So we must understand that relaxed vagina is definite entity and its correction is desirable for good sexual response not only in male partners but also in women themselves.

We have managed 21 women suffering with vaginal relaxation with our technique over five years and achieved good results.

### Material and Methods

We have treated 21 women patients over a period of five years; all of them were married or divorcee. Amongst married group their partners complained that they had lost pleasure of sex. 16 Women complained that they don't get pleasure of sex after delivery. On examination it was found that two fingers were being passed with ease in all women inside vagina (Figure 1) without exertion of pressure. Though we did not measure pressure inside vagina but in all women pressure must be extremely low as no pressure could be exerted on fingers while they

were asked to contract the muscles.

### Techniques

Under spinal anaesthesia lithotomy position was made. Part was prepared and draped. Examination was done before anaesthesia (Figures 1 and 2) then an incision was made posterior to posterior vaginal opening (Figure 3). Mucosa was cut and dissection was done deeper exposing the muscles and fascia (Figure 4). The muscles and fascia were reefed in midline. Then multiple rugae were created inside vagina mostly in posterior and lateral wall (Figure 5).

### How to create rugae

Rugae creation has not been described in literature. We have for the first time described creation of rugae. For this after the mucosa is dissected a fold of mucosa is held in forceps and vicryl suture is passed from one side to other and then from other side to first side and when it is tied lightly a fold is created which is rugae.

After creation of rugae and reefing of muscles the mucosa of vestibule is incised bulbospongiosus muscle dissected on either side and approximated in midline. Excess of mucosa is excised and closed primarily (Figure 6). After completion of operation vagina should barely admit one finger (Figure 7).

The ointment is smeared over the stitches and a pad is applied.

### Postoperative management

Postoperatively the pad is changed by patient every time she goes to toilet and ointment is applied. Antibiotic is given for one dose and pain killers are given for few days. Physical relations are advised after three weeks when complete healing had taken place.

**\*Corresponding author:** Vishwa Prakash, Unit head, Department of Plastic Surgery, Safdarjung Hospital, New Delhi, India, Tel: 9810115227; E-mail: [vpagarwal@gmail.com](mailto:vpagarwal@gmail.com)

Received November 12, 2013; Accepted January 16, 2014; Published January 20, 2014

**Citation:** Prakash V, Garg N (2014) New Technique for Management of Relaxed Vagina –Preliminary Study. Anaplastology 3: 124. doi: [10.4172/2161-1173.1000124](https://doi.org/10.4172/2161-1173.1000124)

**Copyright:** © 2014 Prakash V, et al. This is an open-access article distributed under the terms of the Creative Commons Attribution License, which permits unrestricted use, distribution, and reproduction in any medium, provided the original author and source are credited.

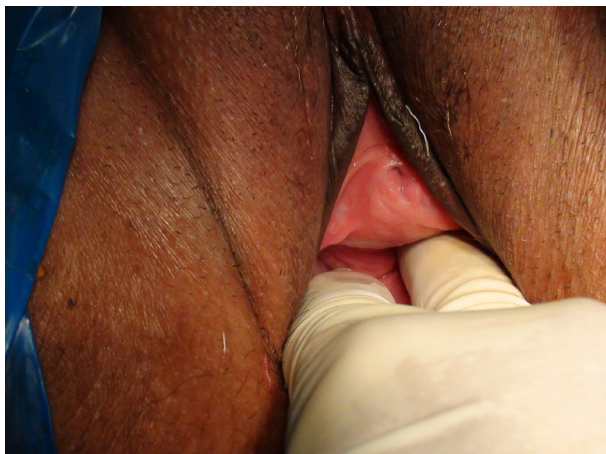

Figure 1: Showing that loose vagina admits two or more fingers with ease.

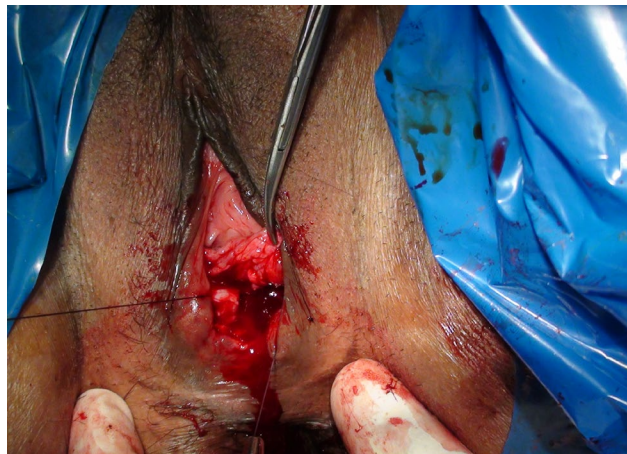


Figure 4: Reefing of muscles and fascia being done.

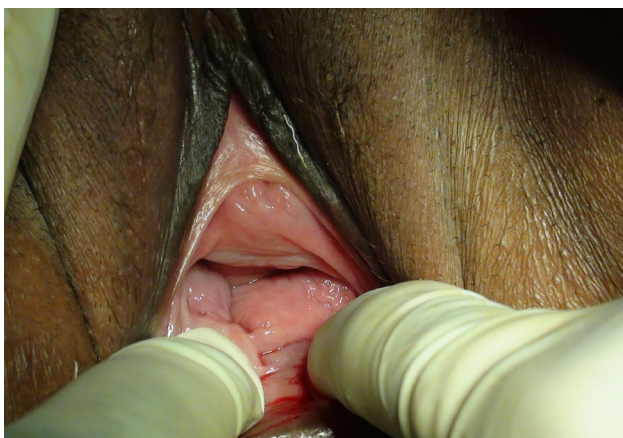


Figure 2: Showing loose vagina.

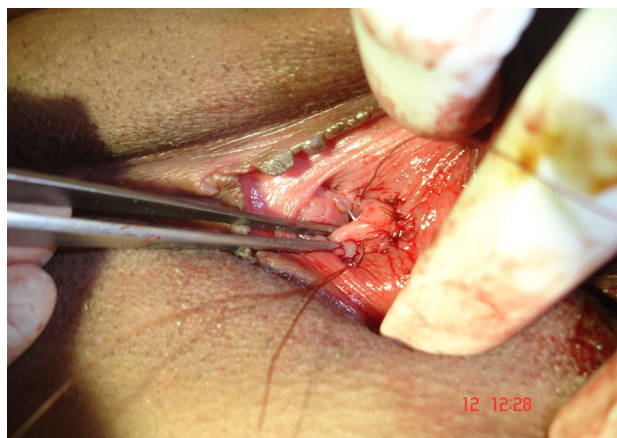

Figure 5: Showing creation of rugae

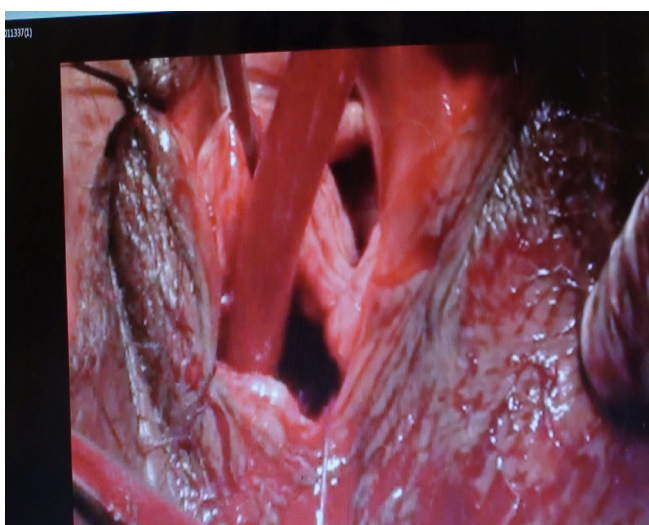


Figure 3: Incision made in vestibule posterior to posterior vaginal wall opening.

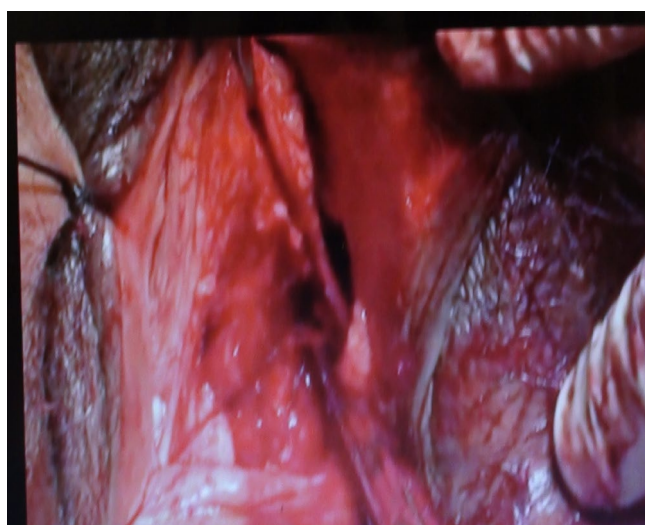
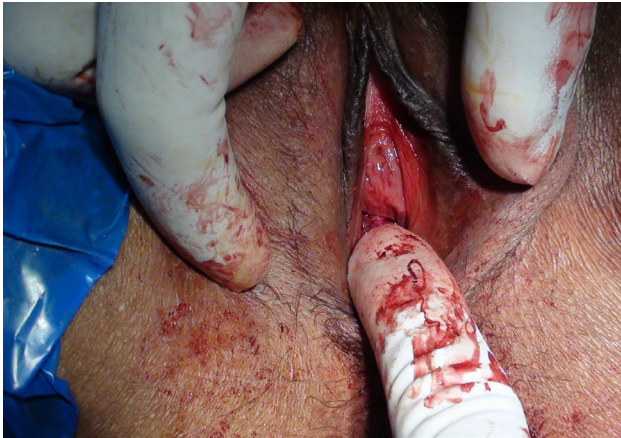
Figure 6: Closing mucosa of vestibule after removal of excess of mucosa.



**Figure 7:** After completion of procedure vagina barely admits one finger.

## Results

All the patients confirmed improved sexual function after operation and experienced same tightness as they had sex for the first time. Though two out of twenty seven said that same tightness could not be maintained after few months but it was better than preoperative state when there was no grip felt of vagina over the penis. The remarkable feature was that none of our patients complained of dyspareunia. Male partners of all except one patient expressed happiness over tightness.

## Discussion

In academic literature it is not described what is loose or tight vagina. Few books have described that in a virgin one should not be able to pass a finger with ease inside vagina but none have described when it should be taken as relaxed vagina. Further vagina is not static tube and can adept any penis of any width, length being of no importance. So when vagina does not grip the penis during sexual intercourse it should be diagnosed as loose or relaxed vagina, or when vagina cannot create a pressure of 15 mmHg during muscle contraction it should be taken as loose vagina. If grip is not there the glans does not strike against G spot and vaginal orgasm in woman is not very good, while for male partner it is grip of vagina over the penis which is responsible for pleasure of sex, which is restored by tightening of vagina. Grip of vagina over glans is also responsible for better erection.

It has been proved that intravaginal pressure is decreased severely after vaginal birth [4]. We could not find any report that aging also involves decreased vaginal pressure or not. However [5] The patients with pelvic relaxation had significantly higher scores of collagen and fewer scores of cellularity within the connective tissue samples, compared with the ones without relaxation ( $p < 0.01$ ,  $p < 0.01$ ). It may be that during aging in many of women vaginal relaxation may be due to decreased fibroblasts and increased collagen content.

We could find only two reports in literature for correction of vaginal relaxation [6,7] in which suturing was done without cutting. We do not agree with this technique because looseness is due to dehiscence of fascia and muscular layer which needs to be approximated. Powell [7] has described a technique of anterior vaginal wall hammock with fascia lata, but author do not agree with this technique.

Usually gynaecologists treat the condition by posterior colporrhaphy removing the V shaped piece of mucosa from the posterior vaginal wall, doing extensive dissection and tightening the levator and deeper muscles. The result is dyspareunia, which is the worst complication anybody can give to a woman. Further most of gynaecologists do not admit to relaxed vagina as a condition which should be treated if there is no cystocele and rectocele. And it is unfortunate as for as the sexual health of a women is considered.

By our method of creating rugae, not excising the mucosa and tightening the muscles as well as bulbospongiosus muscle, vagina is given the virginal status without any fear of dyspareunia.

## Conclusion

The relaxed vagina is a definite entity and it should be recognised for improving the sexual functions of the couple. Our method of creating rugae and muscle tightening along with bulbospongioplasty is a good technique for management of loose vagina in women.

## References

1. Puppo V (2011) Embryology and anatomy of the vulva: the female orgasm and women's sexual health. *Eur J Obstet Gynecol Reprod Biol* 154: 3-8.
2. Levitt EE, Konovsky M, Freese MP, Thompson JF (1979) Intravaginal pressure assessed by the Kegel perineometer. *Arch Sex Behav* 8: 425-430.
3. Shafik A, Shafik AA, El Sibai O, Shafik IA (2007) The response of the corporal tissue and cavernosus muscles to urethral stimulation: an effect of penile buffeting of the vaginal introitus. *J Androl* 28: 853-857.
4. Cai L, Zhang B, Lin H, Xing W, Chen J (2013) Does vaginal delivery affect postnatal coitus? *Int J Impot Res* 26: 24-27.
5. Kokcu A, Yanik F, Cetinkaya M, Alper T, Kandemir B, et al. (2002) Histopathological evaluation of the connective tissue of the vaginal fascia and the uterine ligaments in women with and without pelvic relaxation. *Arch Gynecol Obstet* 266: 75-78.
6. Liu S, Cen Y, Liu Q (2009) Improvement of vaginal relaxation by vaginal narrowing technique with double suturing. *Zhongguo Xiu Fu Chong Jian Wai Ke Za Zhi* 23: 1456-1458.
7. Powell CR, Simsman AJ, Menefee SA (2004) Anterior vaginal wall hammock with fascia lata for the correction of stage 2 or greater anterior vaginal compartment relaxation. *J Urol* 171: 264-267.